Datasheet for ABIN7477453

Recombinant anti-pan Keratin antibody

3 Images

Go to Product page

Overview

Quantity:	1 mL
Target:	pan Keratin (panKRT)
Reactivity:	Human
Host:	Rabbit
Antibody Type:	Recombinant Antibody
Clonality:	Monoclonal
Conjugate:	This pan Keratin antibody is un-conjugated
Application:	Immunohistochemistry (IHC)

Product Details

Clone:	MSVA-000R
Isotype:	IgG

Target Details

Target:	pan Keratin (panKRT)
Alternative Name:	Cytokeratin, Pan (panKRT Products)
Background:	K1B, KRT1B, Keratin, type II cytoskeletal 1b, K77, CK-1B, Keratin 1B, Keratin-77, Cytokeratin-1B, Type-II Keratin Kb39,Cytokeratin, Pan antibody validated for immunohistochemistry on 76 different Normal Tissues
UniProt:	Q7Z794, Q01546

Copyright antibodies-online. All rights reserved.

Application Details

Application Notes:	IHC 1:100-1:200
Comment:	Positive Control: Liver: A strong staining of all bile duct epithelial cells and an at least moderate, predominantly membranous staining of most hepatocytes should be seen. Negative Control: Tonsil: All lymphocytes must not stain. However, interstitial reticulum cells with dendritic/reticular pattern show a weak to moderate fibrillar staining.
Protocol:	Manual Protocol: Freshly cut sections should be used (less than 10 days between cutting and staining). Heat-induced antigen retrieval for 5 minutes in an autoclave at 121 °C in pH 7,8 Target Retrieval Solution buffer. Apply the antibody at a dilution of 1:150 at 37 °C for 60 minutes. Visualization of bound antibody by the EnVision Kit (Dako, Agilent) according to the manufacturer's directions.
Restrictions:	For Research Use only

Handling

Format:	Liquid
Storage:	4 °C,-20 °C,-80 °C
Storage Comment:	Antibody with azide - store at 2 to 8 °C. Antibody without azide - store at -20 to -80 °C. Antibody is stable for 24 months. Non- hazardous.

Images



Immunohistochemistry

Image 1. Tonsil surface epithelium

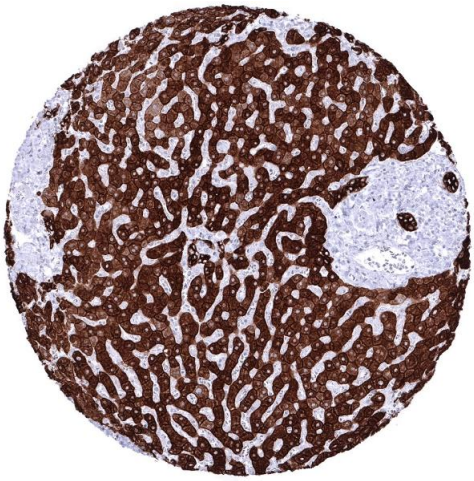

Immunohistochemistry

Image 2. Liver In the liver a strong cytoplasmic staining of all bile ductal epithelial cells and an at least moderate predominantly membranous immunostaining of hepatocytes is seen

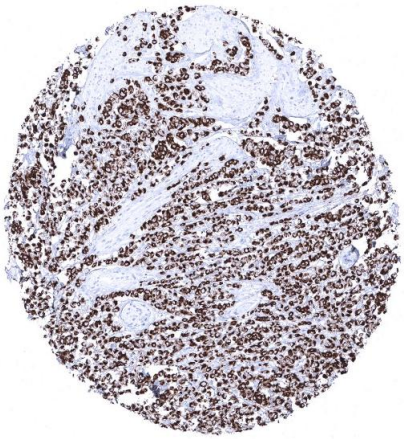

Immunohistochemistry

Image 3. Invasive lobular breast cancer showing strong diffuse CKpan positivity in tumor cells

 Copyright antibodies-online. All rights reserved.